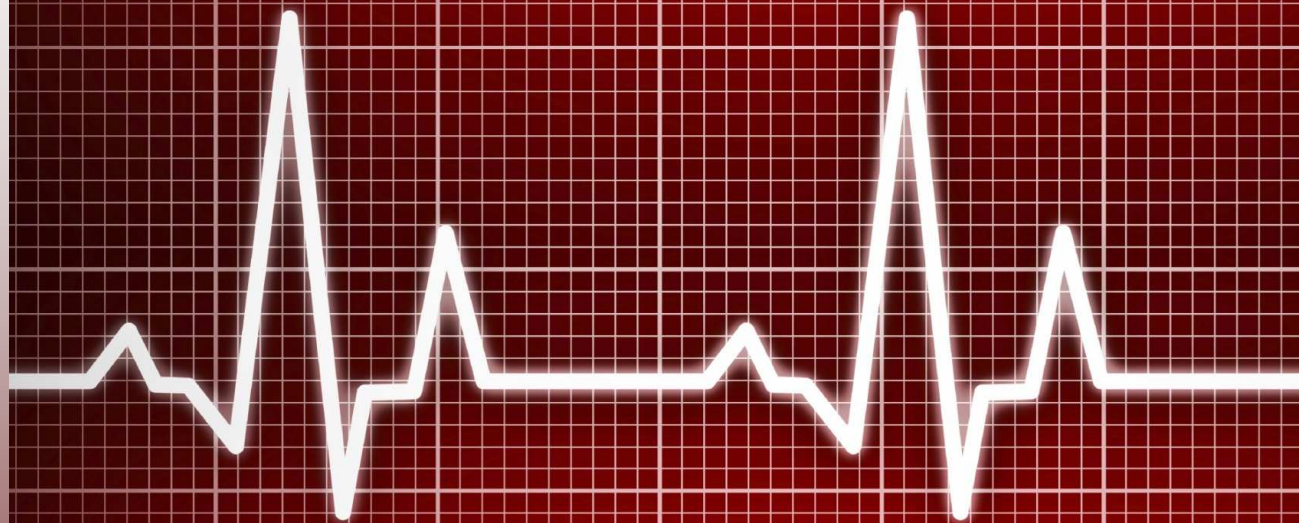


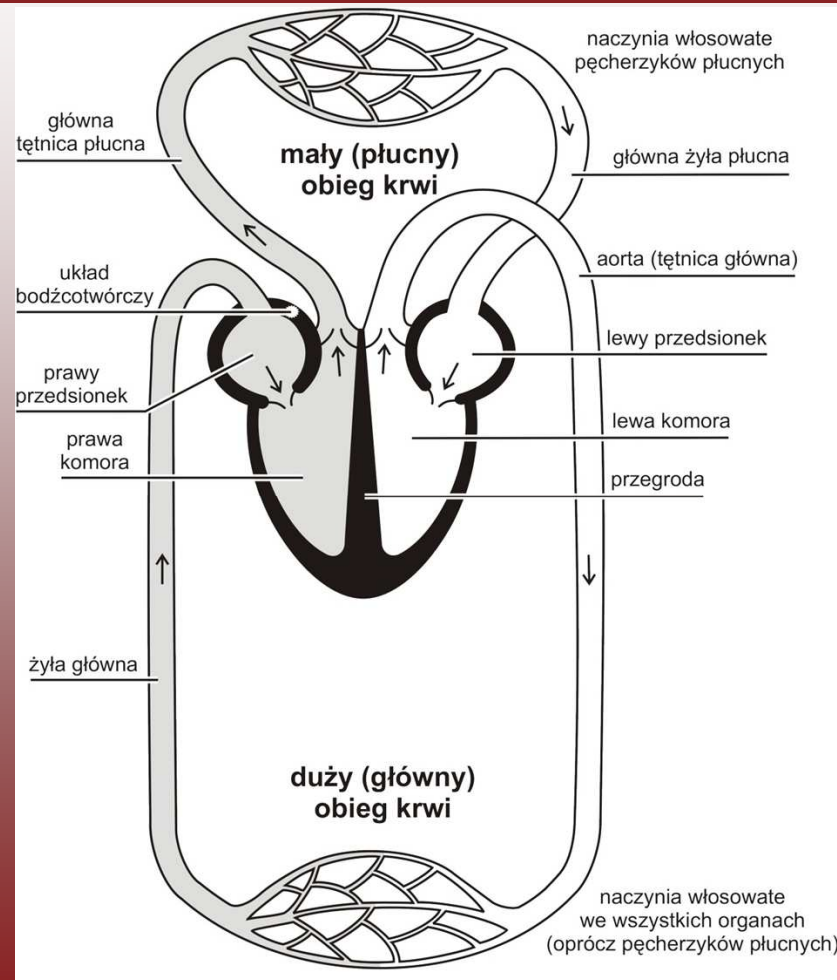
# **TA**

**ATREZJA ZASTAWKI TRÓJDZIELNEJ**

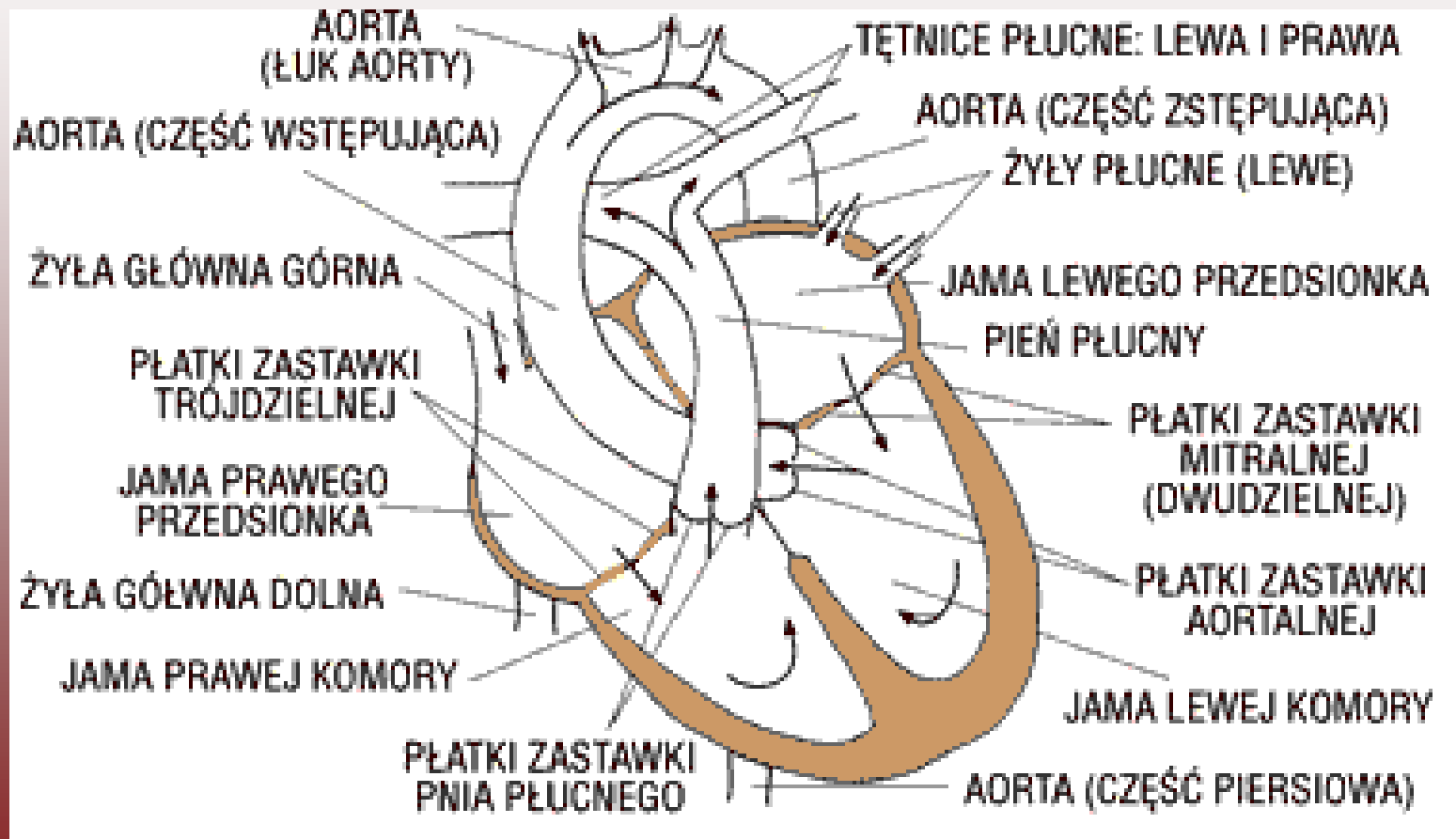
**HANNA MILEWSKA**



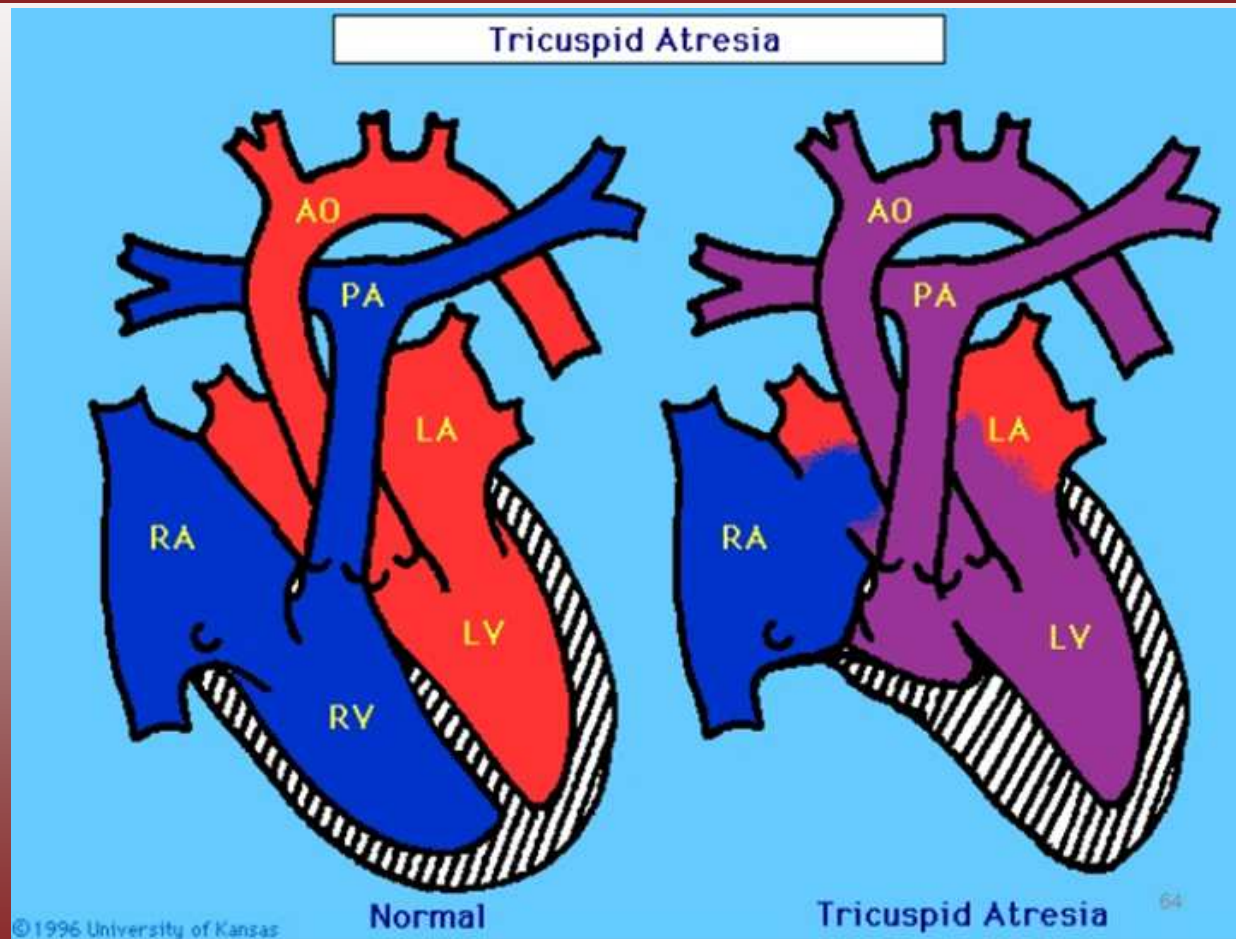
# SCHEMAT UKŁADU KRWIONOŚNEGO CZŁOWIEKA



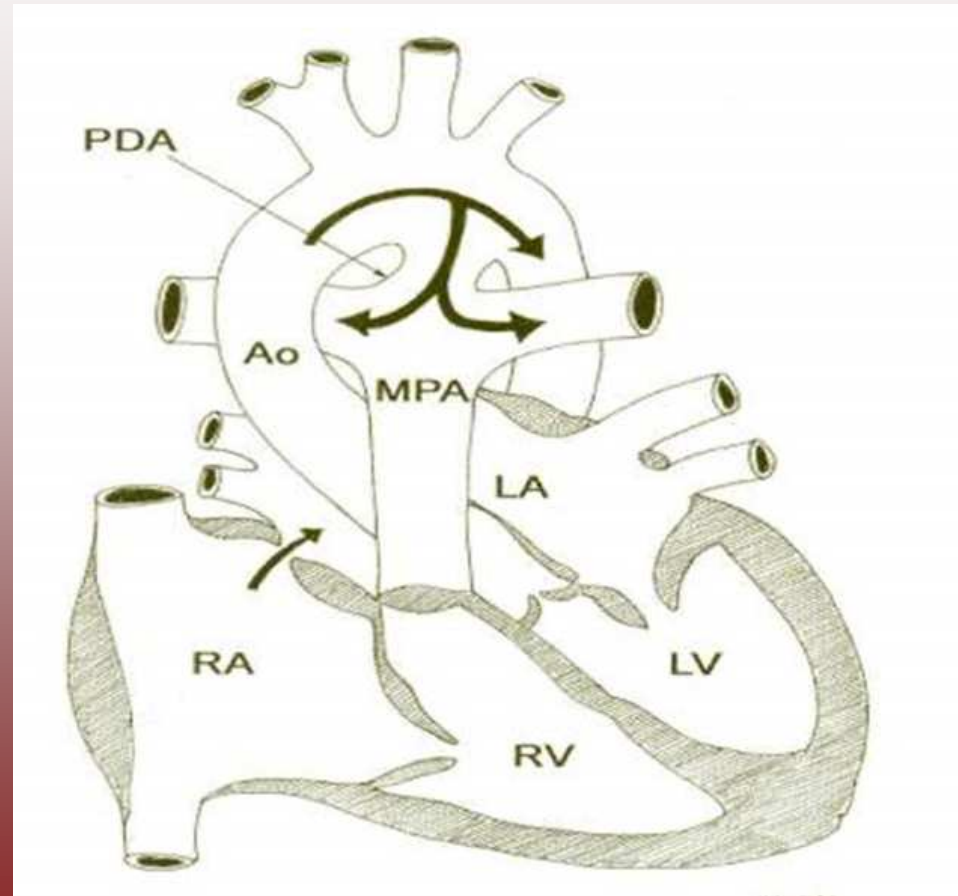
# BUDOWA SERCA



# ATREZJA ZASTAWKI TRÓJDZIELNEJ

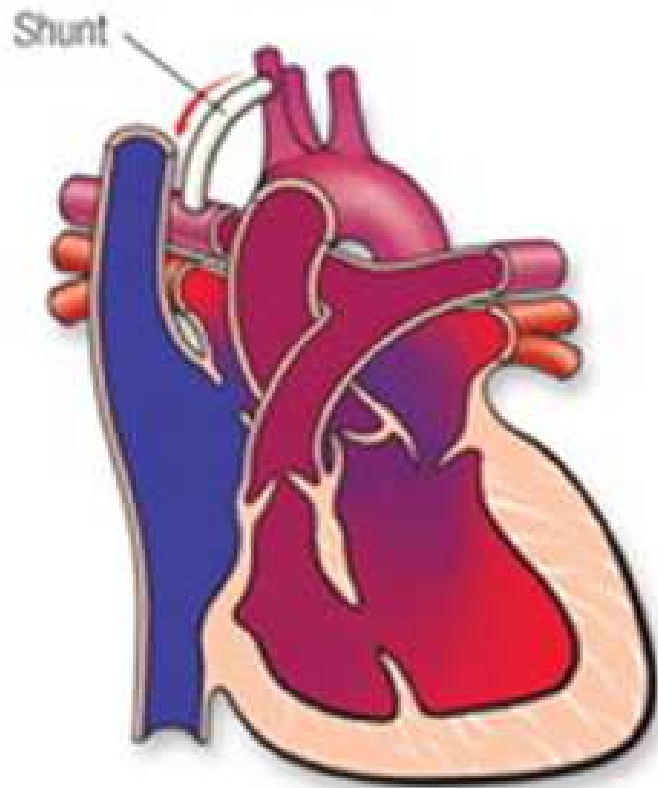


# PRZEWÓD BOTALLA

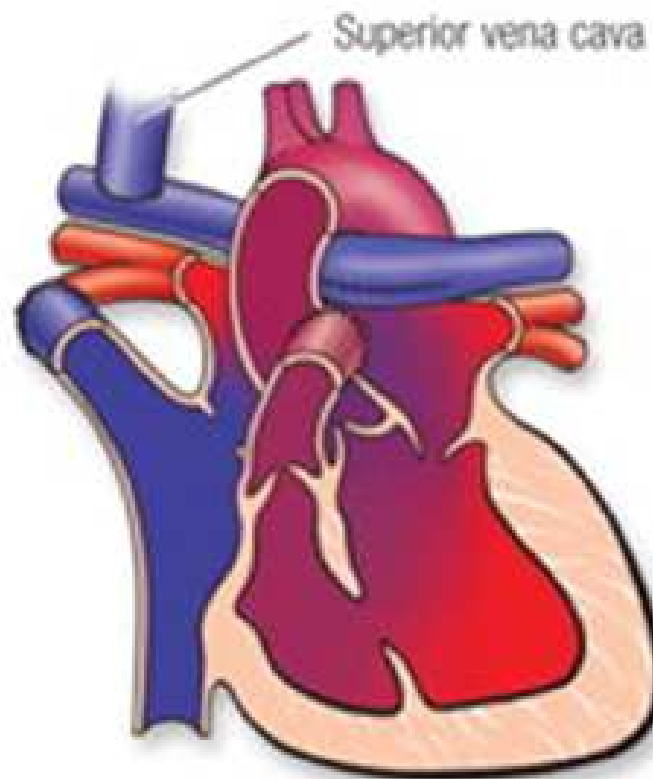


# TRÓJETAPOWE LECZENIE

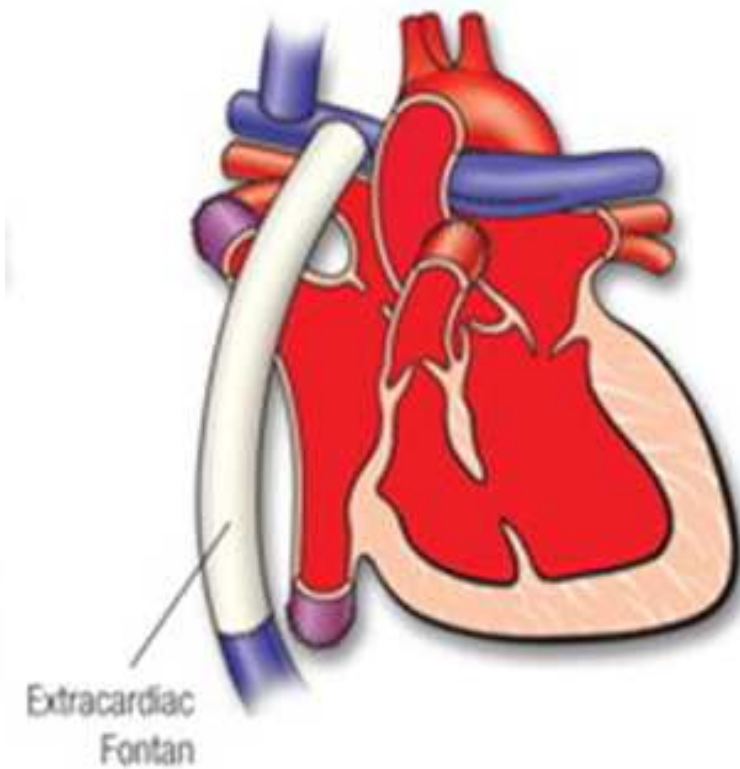
Shunt



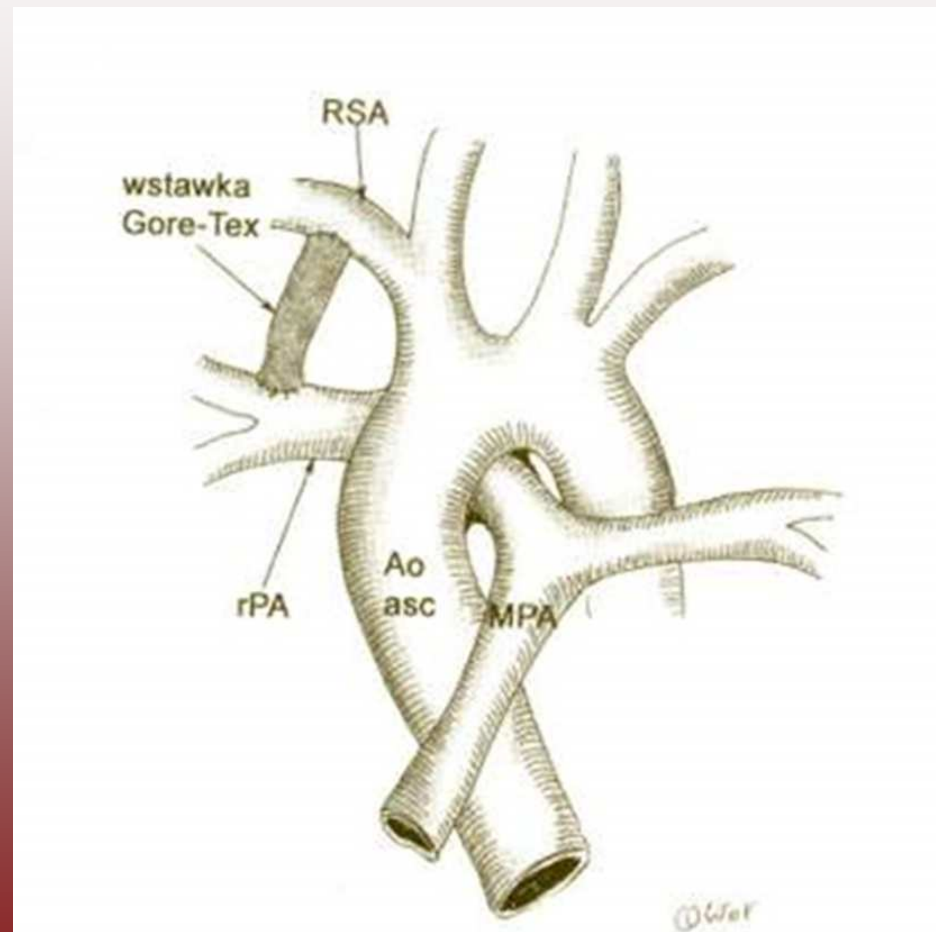
Bidirectional Glenn



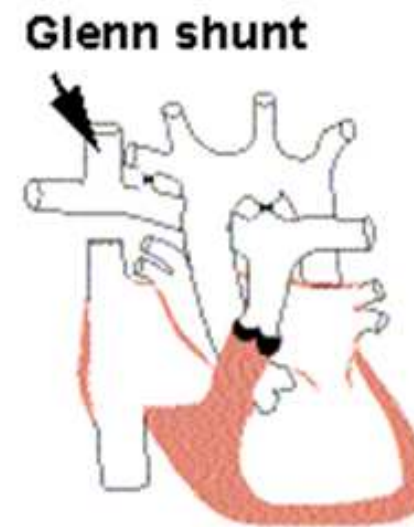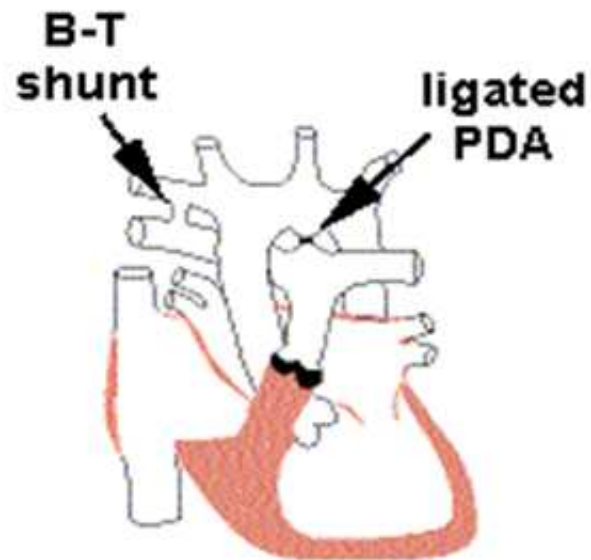
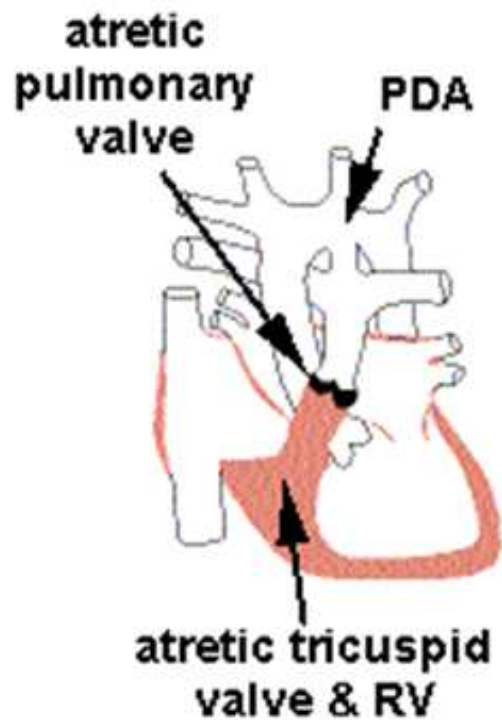
Fontan



# ZESPOLENIE SYSTEMOWO-PŁUCNE BLALOCK-TAUSIG

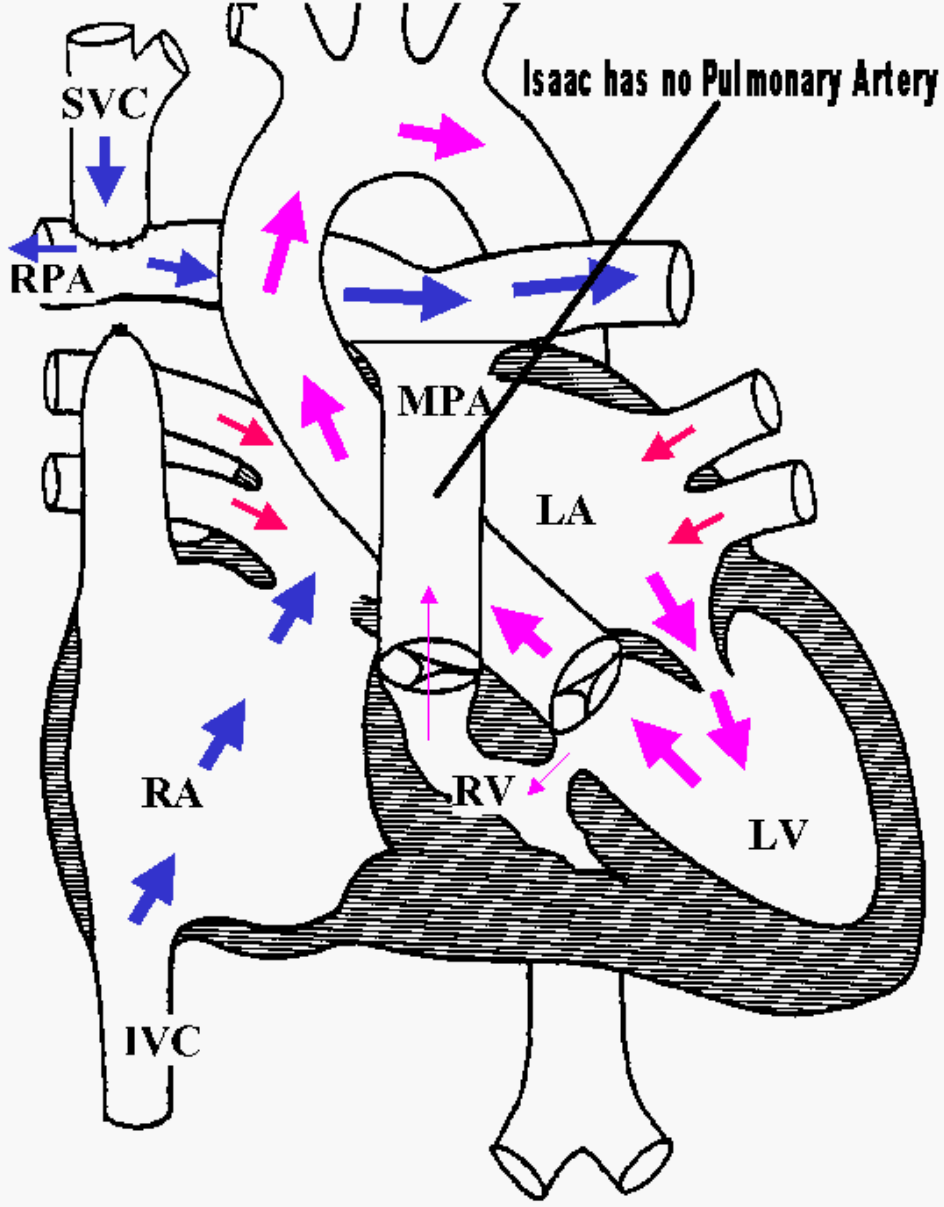


# ZESPOLENIE GLENNA

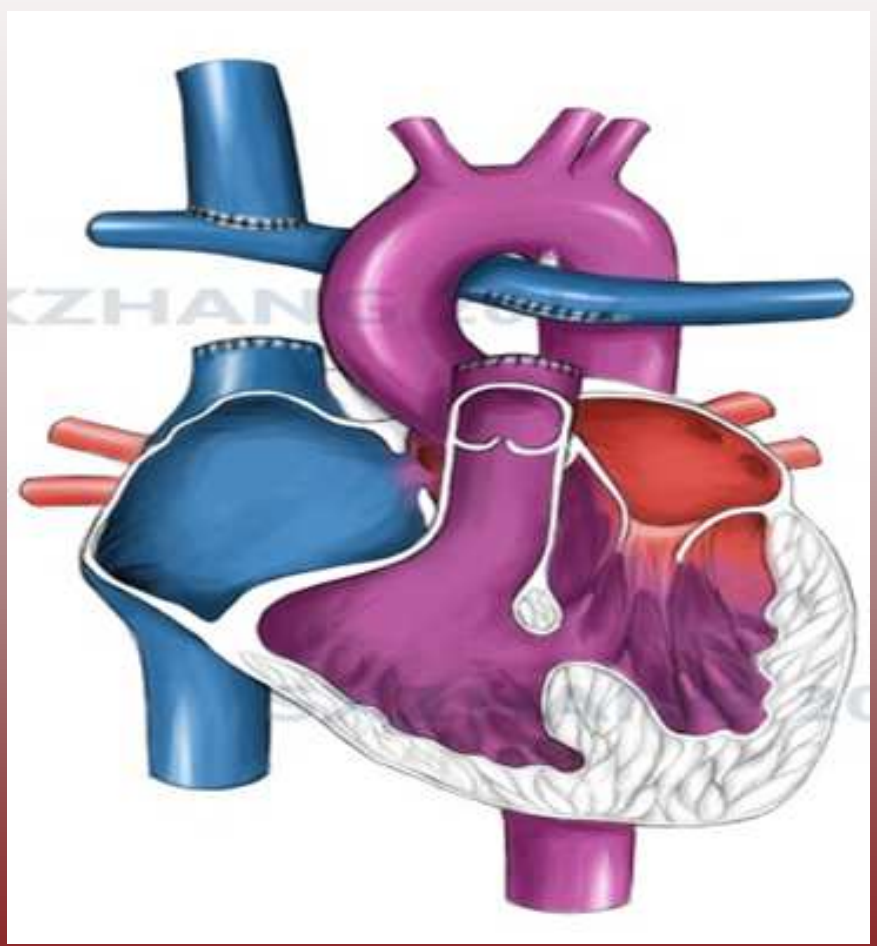




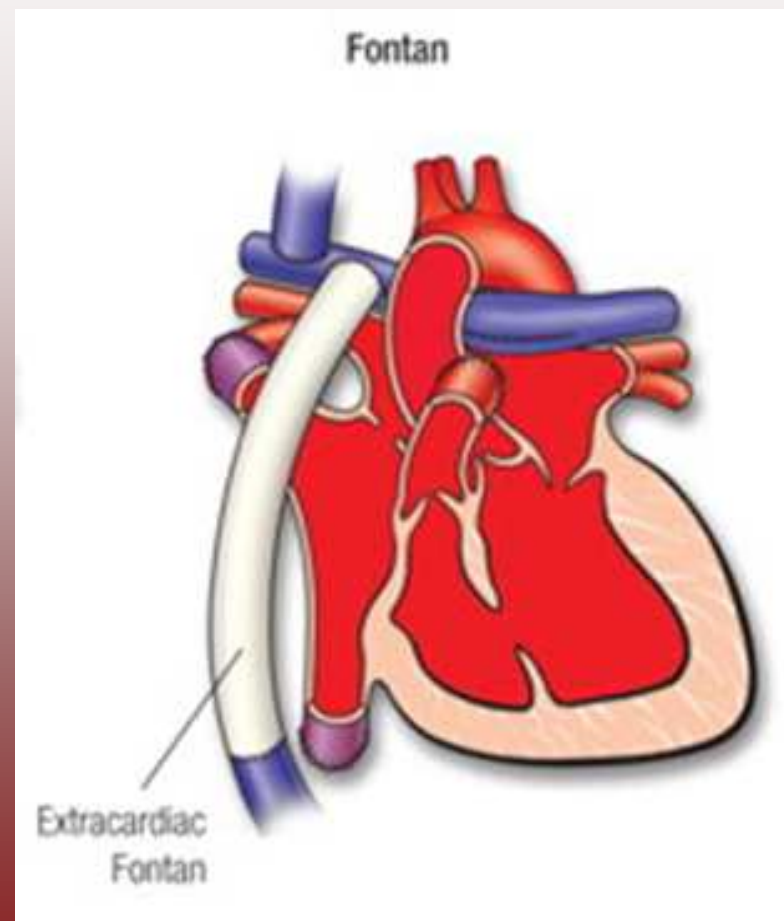
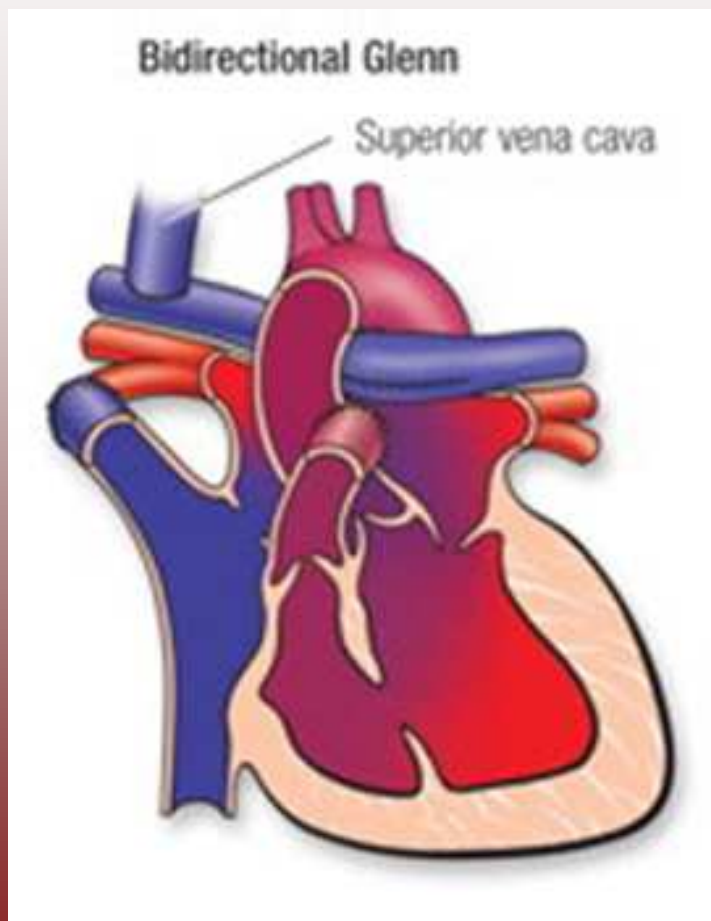
# TRICUSPID ATRESIA - S/P GLENN SHUNT



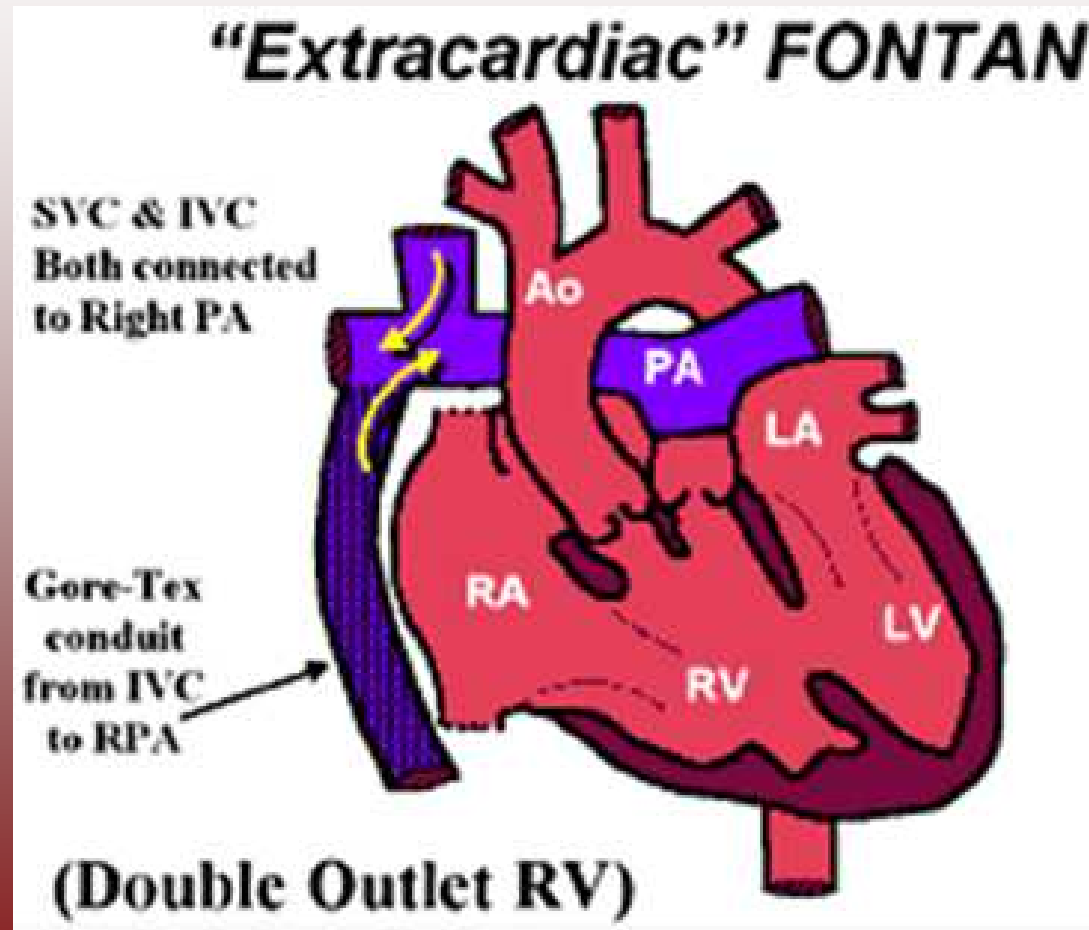
# SERCE PO ZESPOLENIU GLENNA



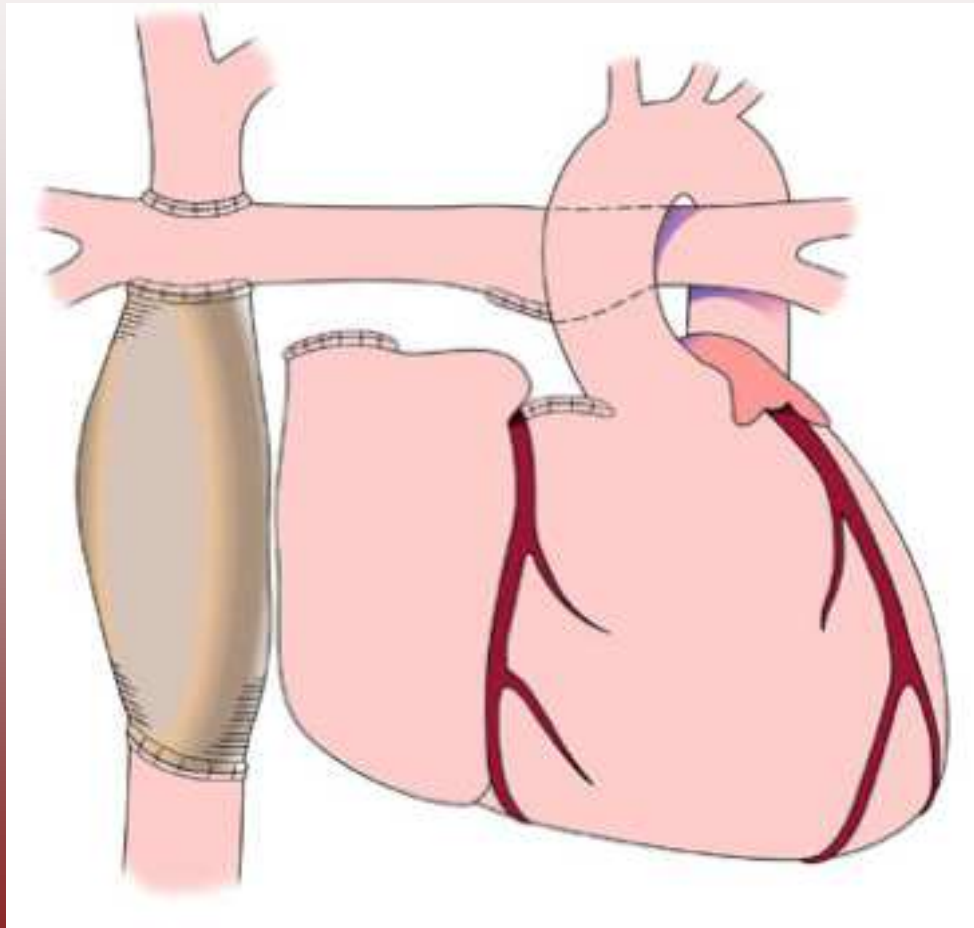
# ZESPOLENIE FONTANA



# AT PO ZESPOLENIU FONTANA



# EFEKT PO TRZECH OPERACJACH



**DZIĘKUJĘ**

**ZA**

**UWAGĘ**

